

Impact of combinatory growth factor application on rabbit Achilles tendon injury with operative versus conservative treatment: A pilot study

MORITZ A. KONERDING¹, FRIEDERIKE ARLT¹, AXEL WELLMANN², VINCENT LI³ and WILLIAM LI⁴

¹Institute of Anatomy and Cell Biology, University Medical Center of the Johannes Gutenberg University Mainz, Medical School, D-55099 Mainz; ²Institute of Pathology Celle, D-29223 Celle, Germany; ³The Wound Healing Clinic, Brigham and Women's Hospital, Boston, MA; ⁴The Angiogenesis Foundation, Boston, MA, USA

Received September 21, 2009; Accepted November 3, 2009

DOI: 10.3892/ijmm_00000333

Abstract. Acute Achilles tendon (AT) rupture is a common injury with a comparatively high complication rate. Presently, surgical treatments compete with nonoperative treatment modalities. The aim of this study was to elucidate the possible beneficial effects of short-term combinatory application of growth factors on tendon healing during operative or conservative treatment. In this controlled laboratory study, the left ATs of 40 adult New Zealand White rabbits were transected and either sutured or treated conservatively. Half of the animals from each treatment modality group repetitively received a mixture of VEGF165, bFGF, and rPDGF which was administered peritendineally. The left legs were immobilized with external fixateurs for 6 weeks. The ATs were harvested 3 months after intervention. Tensile strength tests revealed no significant differences between operative and conservative treatments. Compared to the normal right ATs, 60% of the average breaking strength was reached 3 months after surgery. Growth factor application did not result in significant improvements. Only a tendency towards higher blood vessel densities was noted in the groups treated with the factors. Collagen type I/III ratios also displayed no significant differences. This study indicates that there is no difference in the biomechanical outcome of conservative versus operative AT rupture treatment and only a marginal impact of short-term combinatory growth and angiogenesis factor application.

Introduction

Optimization of wound healing is a topic which is currently attracting much attention. An increasing life expectancy and

an ageing population are paralleled by increasing medical costs for treatment of chronic wounds. Despite numerous recent advances in wound care management there is a strong need for improved treatment strategies. Application of growth and angiogenesis factors, among others, seems to be a promising tool for speeding up the process of wound healing. However, most studies on wound healing improvement have been carried out in skin wound models, which do not allow for predictions concerning the efficacy of cell-attracting factors for acute wounds and/or bradytrophic tissue injury such as the tendon.

Acute Achilles tendon (AT) rupture is a common tendon injury with an incidence of 18 per 100,000 and is thought to be rising (1). Long recovery, late return to work, high rerupture and other complication rates are typical for AT ruptures.

Despite 20 years of continuous discussion, there is still a lack of consensus regarding the best option for the treatment of acute AT rupture (2). Operative treatments compete against various nonoperative treatment modalities such as casting or functional bracing. Khan *et al* (2) performed a meta-analysis of randomized, controlled trials on the treatment of acute AT rupture treatments and highlighted the fact that open operative treatment significantly reduces the risk of rerupture, whereas nonoperative treatment is associated with a significantly lower risk of other complications.

More recent controlled trials comparing minimally invasive surgery versus nonoperative treatment suggest comparable rerupture rates and a lower incidence of other complications (3). However, return to work was significantly longer following nonoperative treatments.

There is some evidence that growth factors may make injured tendons heal faster (4-7). However, surprisingly little research has been conducted to exploit this possible treatment modality as pointed out in a recent review (4).

Factors such as VEGF, bFGF, and PDGF have shown reasonable therapeutic effects in skin wound healing such as in the case of diabetic ulcers and has proven to also be effective in experimental tendon or ligament repair (7,8). Most studies were confined to the evaluation of the early effects of a single individual factor. We hypothesized that short-term combinatory application of some key mitogenic and angiogenic factors would improve the long term functional outcome of AT injury.

Correspondence to: Dr Moritz A. Konerding, Institute of Anatomy and Cell Biology, University Medical Center of the Johannes Gutenberg University Mainz, Saarstrasse 13-18, D-55099 Mainz, Germany

E-mail: konerdin@uni-mainz.de

Key words: Achilles tendon injury, growth factors, operative treatment, conservative treatment, rabbit

In order to test this hypothesis, the effects of repetitive, combined growth factor application on the healing of transected ATs both after operative surgery and nonoperative surgery were assessed in a rabbit AT rupture model. The primary end point was the maximum tensile strength of the transected AT 3 months after intervention, and secondary end points consisted of a series of histological parameters.

Materials and methods

Animals. Forty female New Zealand White rabbits with an average weight of 3 kg were obtained from Charles River. The 16- to 20-week-old animals were maintained individually in cages in an animal house room at $21.5 \pm 2^\circ\text{C}$ with 70% relative humidity and 15-fold air renewal per hour according to the legal regulations. Light/dark cycles were 12/12 h. Animals received standardized dry rabbit diet, sterilized hay, and water *ad libitum*. All experiments were conducted with the approval of the local animal welfare authorities (licence no. 23 177-07/G 06 -1-022).

Treatment groups. Four groups with eight animals each were randomized. The remaining eight rabbits were used as reserve animals to replace premature drop-outs. Group 1 received operative treatment plus repetitive administration of the growth factor cocktail; group 2, operative treatment and no growth factors. Group 3 received conservative treatment plus repetitive administration of the growth factor cocktail; group 4, conservative treatment and no growth factors.

Surgery. The day before surgery, the left lower limb was shaved under sedation with 10 mg diazepam (Diazep; Ratiopharm, Ulm, Germany). Surgery was performed under strictly aseptic conditions and always by the same surgeon. Premedication consisted of 0.1 ml/kg body weight (b.w.) acepromazine (Prequilan; Fatro, Ozzano Emilia, Italy), and anesthesia was performed with ketamine hydrochloride (Ketavet, 100 mg/ml, 0.5 ml/kg b.w.; Pfizer, Berlin, Germany) and xylazine (Rompun, 2%, 0.25 ml/kg b.w.; Bayer, Leverkusen, Germany). Antibiotic prophylaxis was carried out perioperatively as well as daily until day 5 with 0.1 ml/kg b.w. marbofloxacin, a gyrase-inhibitor (Marbocyl 2%, Vetoquinol, Vienna, Austria).

Animals were fixed in the left lateral position, and following skin disinfection, the AT was exposed with a 2-cm skin incision followed by blunt dissection. After scalpel transection of the tendons in the medial third and careful hemostasis, the incisional wounds of the animals of the groups undergoing conservative treatment (groups 3 and 4) were sutured with Prolene 3-0 (Ethicon, Norderstedt, Germany). Immediately after skin closure, the group 3 animals received the first growth factor cocktail peritendineally. In group 1 and 2 animals, the transected ATs were sutured using the Kirchmayr technique before hemostasis, application of growth factors (group 1), and skin closure.

In all animals, the left leg was immobilized in plantar deflection for 6 weeks by means of an external fixateur made of three Kirschner wires (diameter: 1.0 mm) that were drilled through the tibia head, the calcaneus and metatarsus. After cutting and bending, the K-wires were fixed medially and

laterally by manually moulding an anchor of Technovit 3040, a fast-curing methyl methacrylate-based resin (Fig. 1).

Growth factors. Animals of groups 1 and 3 received perioperatively as well as on days 3, 5, and 7 a cocktail consisting of PDGF (1.17 μg), FGF-II (0.83 μg) and VEGF (3.3 μg) (all from R&D Systems, Wiesbaden, Germany), which was administered peritendineally using an insulin syringe. Initially, a 3-fold higher dosage was planned [PDGF (3.50 μg), FGF-II (2.50 μg) and VEGF (10.0 μg)]. Two animals, however, experienced severe immune reactions in the form of an endotoxin reaction despite a negative Limulus test of the substances and declared non-evidence of endotoxins. The clinical symptoms were high fever and locally severe inflammatory edema and bleeding at the site of surgery and factor administration. Autopsy did not reveal any organ damage. Therefore, the dosages of new charges were reduced, and the animals replaced. No further systemic reactions were observed.

Side effects. In two further animals, skin lesions in the form of pressure sores were observed. These and four other cases of skin lesions caused by licking were successfully treated with silver spray. In two animals, the external fixateurs needed to be extracted 2 weeks earlier than planned, and one animal had to be sacrificed due to an accidentally torn claw.

Tissue sampling. Three months after surgery and 6 weeks after fixateur extraction, the animals were sacrificed with pentobarbital (Narcoren; Merial, Hallbergmoos, Germany). The healed ATs as well as the contralateral native control ATs were harvested. This was performed proximally by cutting the muscles and distally by cutting the calcaneal tuberosity.

After photographic documentation and measurement of the AT diameters, the maximum tensile strength was determined in every other transected AT (half of each study group) with a self-constructed breaking strength test device consisting of two opposing gripping jaws for fixation of the calcaneus and the proximal part of the tendons (9). The gripping jaws had a serrated finish to avoid the problem of grip slippage and were moved apart by an electric motor at a constant speed of 3 mm/sec, which resulted in load onset rates of <0.05 N/s. The end point was the ultimate load in N at which tendon disruption occurred. A position encoder (WA300) was used to register the covered distance, and a force transducer for traction and compression (S2, maximum value 500 N) was used to quantify the power impacting on the tendons. The resulting values were recorded by a multiple channel PC measuring device (Spider 8) and plotted as a distance-power curve (software, Catman 3.0; both from HBM Hottinger Baldwin Messtechnik, Darmstadt, Germany).

Tissue samples of the ATs were taken from the other half of the study groups and embedded and stained according to standard protocols for anti-CD31 for the manual assessment of microvessel density by means of a modified Weibel grid (10) superimposed over the histological sections. Adjacent sections were stained with picosirius red for polarization microscopic visualization of birefringent patterns reflecting the structural organization of collagen fibrils and for semi-quantitative assessment of collagen type I/type III ratios

(11,12), whereas H&E staining was performed for standard histopathology.

The contralateral non-transected healthy ATs were used as controls. Half were used for maximum tensile strength testing, and the other half was processed for immunostaining and histology as described above.

Statistical analysis. Results are expressed as means unless stated otherwise. Differences between groups were assessed by the Student's t-test for independent, unpaired samples and by ANOVA. The significance level was set at 5% for all comparisons.

Results

Anatomic preliminary remarks. In humans, the AT is formed by the merging of the gastrocnemius and soleus muscles and inserts crescent-shaped corresponding to the posterior calcaneal prominence at the calcaneal tuberosity (13). In rabbits, there are some notable differences. The AT equivalent consists basically of a superficial and a profound part (Fig. 2). The superficial part is composed of the medial and lateral heads of the gastrocnemius muscle, the deeper lying part by the superficial flexor digitorum muscle. Both parts do not merge, and only the gastrocnemius muscle inserts at the dorsal calcaneal circumference. Distally, the tendon of the superficial flexor digitorum muscle comes up superficially and runs as a broad calcaneal galea around the calcaneus tuberosity, using the latter as a hypomochlion, towards the plantar foot side. Luxations are prevented by medial and lateral retinacula. In the present study, both parts of the AT were dissected in every case.

Macroscopic appearance. All tendons harvested after 3 months were noted to have healed properly. Even those that were not sutured (groups 3 and 4) bridged the ≤ 20 -mm-long dehiscency after transection. The peritendineum of the tendons treated with growth factors appeared to be more densely vascularized (Fig. 3a). In general, the sutured ATs were shorter and thicker in appearance, whereas the non-sutured ones appeared elongated and more slender. Even so, Fig. 3c shows that there was no significant difference in tendon width between the sutured and non-sutured ATs (median 4.7 vs. 5.3 mm). Growth factor application also did not influence the width of the ATs.

Tensile strength test. Fig. 4a shows that sutured and non-sutured ATs reached nearly identical maximum tensile strengths (median 245.0 vs 253.4 N). Compared to the non-transected right ATs, the average values reached $\sim 60\%$ 3 months after intervention. Figs. 4b and c show that growth factor application did not improve the outcome.

Collagen contents. As expected, polarized light microscopy showed significantly higher percentual amounts of collagen type III in all test groups as compared to the right control tendons and less collagen type I (Fig. 5). There was a tendency towards higher type III values in the growth factor-treated groups 1 and 3, indicating a higher fraction of juvenile, fine fibrils with a lower degree of crosslinking.

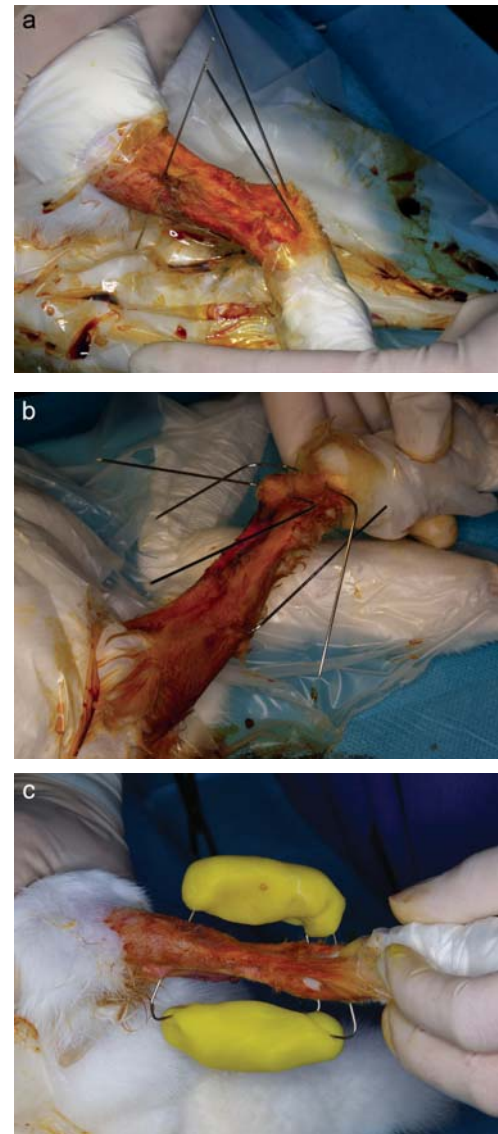


Figure 1. Postoperative immobilization. Three K-wires were drilled through the calcaneus, forefoot and tibial plateau (a). After bending the wires (b), a rapid polymerizing resin was moulded around them (c).

Vessel densities. The normal rabbit AT contains nourishing vessels only in the peritendineum. They may also be found in bands of loose connective tissue between individual parts of the AT. All transected ATs had higher vessel densities, measured as the percentual vessel surface area in longitudinal sections (Fig. 6). The highest values were noted in the sutured ATs. The mean vessel densities tended to be higher in the growth factor-treated groups, although this difference was not significant (median 6.39 vs 3.08%).

Discussion

This pilot study was designed to evaluate the long-term effects of repetitive and combined growth factor application on the healing of transected ATs in a rabbit model, both after surgical and nonoperative treatment. Therefore, the experimental design included only one follow-up time point. The main finding was that neither surgery nor the growth factor cocktail were capable of improving the therapeutic outcome.

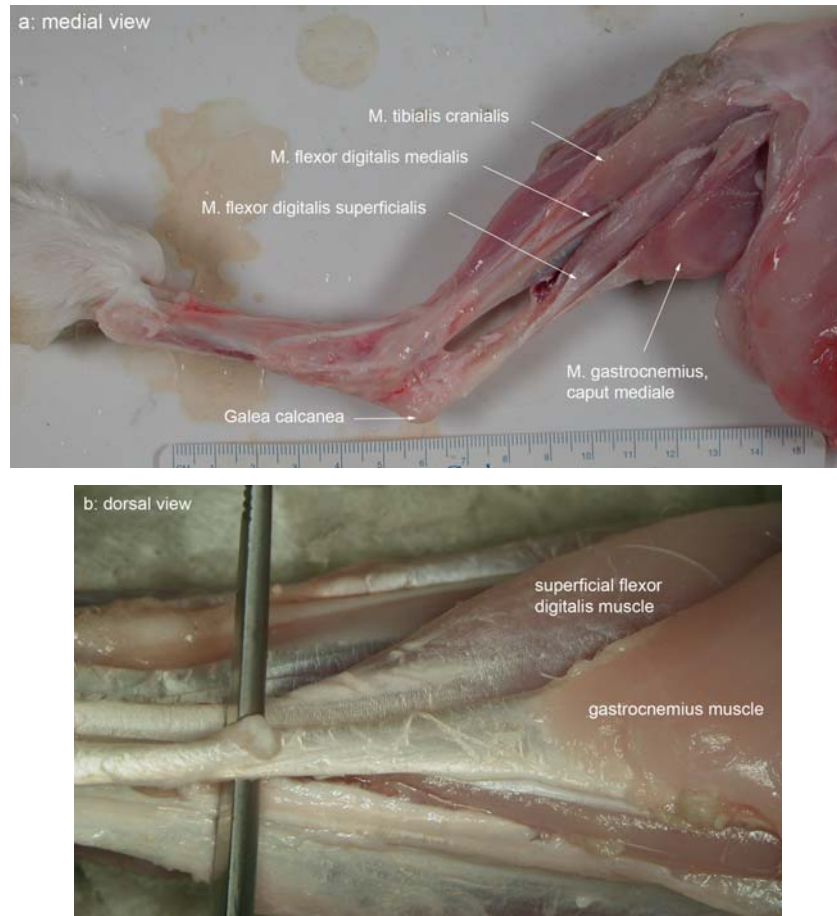

Figure 2. Macroscopic anatomy of the rabbit AT: (a) medial and (b) dorsal view. The gastrocnemius muscle inserts at the calcaneal tuberosity whereas the superficial toe flexor muscle runs around the calcaneal tuberosity. Both tendons compose the AT but are not fused together.

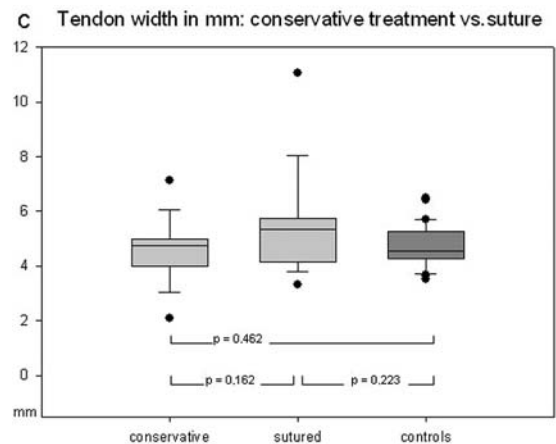
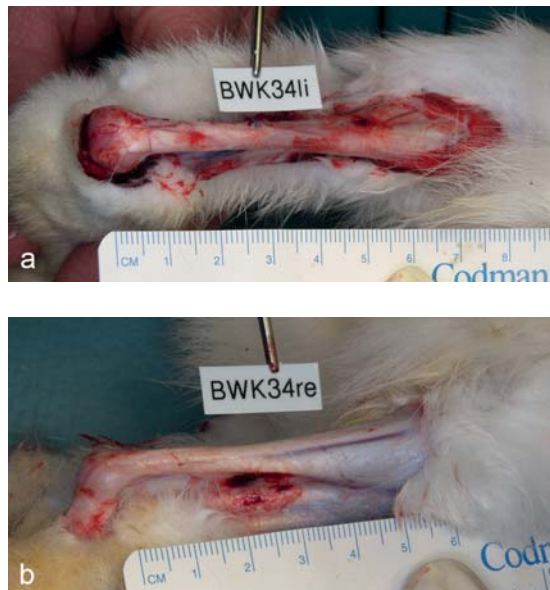

Figure 3. Dimensions and gross appearance of a transected, sutured and growth factor-treated AT (a) and contralateral control (b). The box-whisker plot (c) shows tendon widths in the different experimental groups.

There are, however, some factors inherent to the model used, which might have influenced these results. The common view is that in humans, AT ruptures occur in previously altered tendons (14). A huge variety of contributing etiological factors have been identified (2). Contrary to the human situation, the present study was performed on healthy animals without risk factors which might lead to impaired wound

healing. In wound healing studies in mice, we recently observed that an identical combination of growth factors was as beneficial in animals with impaired wound healing after diabetes induction as in normal animals (unpublished data). On the basis of the results obtained in mice, it seemed appropriate to carry out a similar study both in healthy normoglycemic rabbits as well as in diabetic rabbits exhibiting

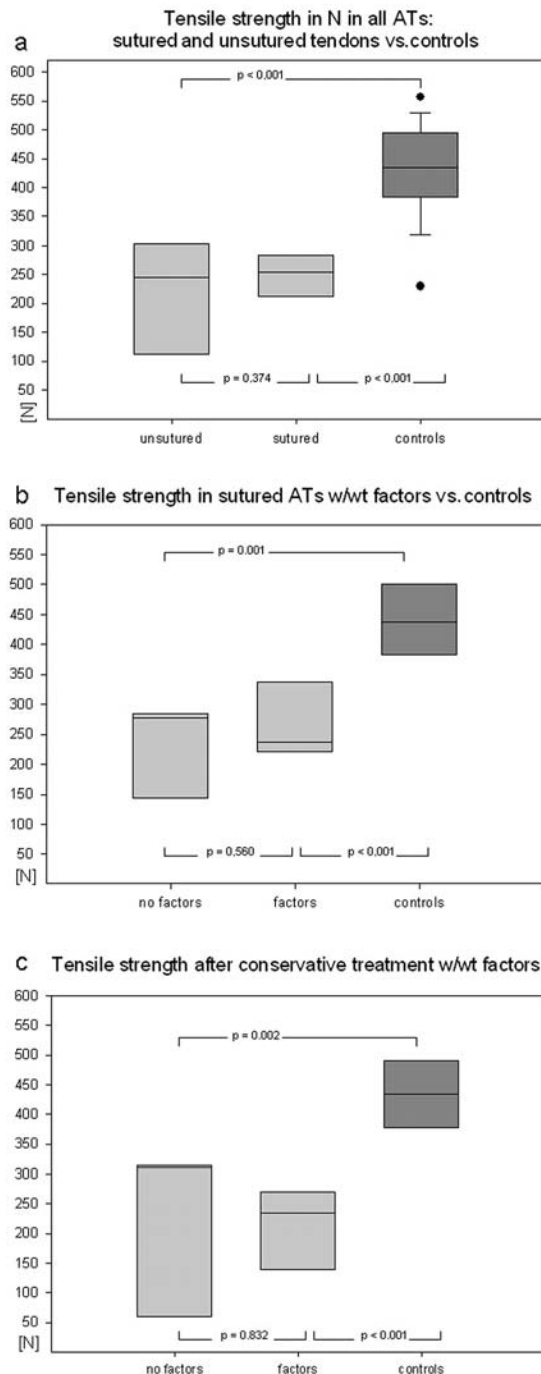


Figure 4. (a) Tensile strength test results in sutured and conservatively treated tendons. (b) Data for operatively treated tendons with a comparison of growth factor-treated tendons versus surgery only with and without factors. (c) Effects of growth factors in conservatively treated ATs.

a severe impairment of wound healing. However, induction of diabetes with streptozotocin or alloxan in rabbits or guinea pigs results in unacceptably high mortalities (15), so we opted to carry out the study in normoglycemic animals only.

A surprising result was that nonoperative treatment resulted in the same tensile strength, despite the wide dehiscences that were not avoided by fixation of the feet in plantar flexion. Thus, in the non-sutured groups, the total amount of newly formed collagen needed to be higher than in the sutured groups. Others (16) have hypothesized that the

closer reinforcing grafts are to the repair zone, the more strength the healed tendon achieves. In fact, they found significant differences in maximum load in rabbit ATs augmented with intratendinous plantaris tendon grafts versus end-to-end repair followed by peritendinous reinforcement graft (16). The observation time was, however, limited to 6 weeks. Since we noted that after 12 weeks only 60% of the tensile strength was reached and that there were still significant differences in collagen type I and type III ratios, it is evident that the long-term outcome cannot be confidently assessed after a period of only 6 weeks. For assessment of matrix remodeling in the healing rabbit AT as carried out on day 15 by Reddy *et al* (17), such early time points make more sense.

Since our data were obtained from a healthy animal experiment collective, it is not entirely comparable to the situation in human AT ruptures. At present, therefore, a contribution to the continued discussion on the pros and cons of conservative therapy versus surgical treatment does not seem appropriate.

In addition, our experimental setting prohibits direct extrapolation to the clinical situation since we had to immobilize also the surgically repaired tendons following IRB requests. This does not duplicate the clinical situation where surgically repaired tendons can be rehabilitated more aggressively with early motion and use. Reproducible immobilization of all tendons over the same period was deemed the better choice compared with poorly controllable non-standardized early rabbit rehabilitation.

At first glance, our findings would appear to contradict those of other groups who investigated growth factor application. Kurtz *et al* (18) described accelerated recovery after IGF-1 application on day 15 following rat AT transection. Forslund and Aspenberg (6) noted improved tendon repair in rabbit AT defects after CDMP-2 (cartilage-derived morphogenetic protein) application after 8 days and Hildebrand *et al* (19) showed improved ultimate load in rabbit medial collateral ligaments 6 weeks after PDGF-BB application. Zhang *et al* (7) reported higher early tensile strengths 1 and 2 weeks after surgery in a rat AT repair model with intact plantaris tendon and VEGF application, but failed to show significant differences after 4 weeks. Modified Kessler suturing and VEGF application without plantaris tendon support also showed no differences. Bolt *et al* (5) showed a positive effect of BMP-14 gene therapy on rat AT injuries, 1-3 weeks after surgery.

The common denominator in all of these studies is that the chosen time points were quite early in comparison to our 12-week trial, in which we regained only 60% of the original tensile strength. Positive results at early points in time parallel previous skin wound healing studies, where the most advantageous results were found at very early stages. Pierce *et al* (20), for example, showed that a single application of rPDGF-B resulted in a 170% increase in the breaking strength of incisional wounds during the first days. However, this apparently pronounced increase in breaking strength is first put into perspective when we consider the fact that less than 10% of the normal skin's breaking strength is reached at this time point (21).

In the present study, a combinatory growth factor application was chosen since we previously observed better

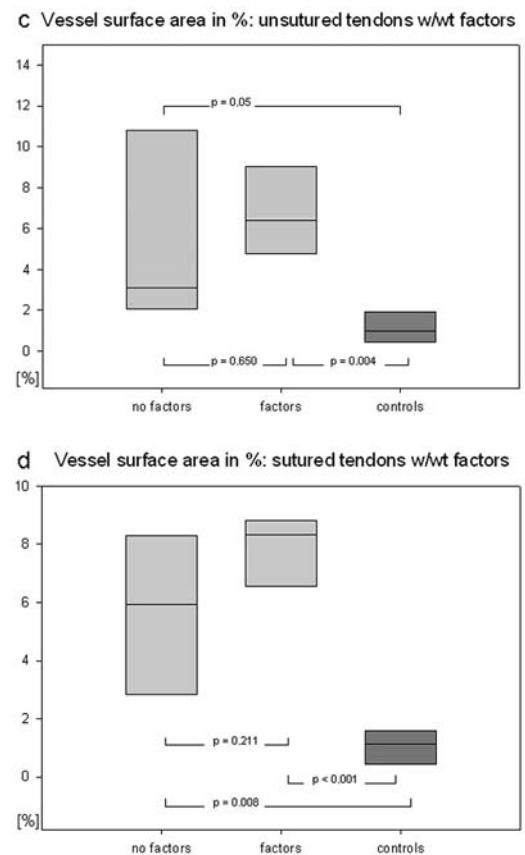
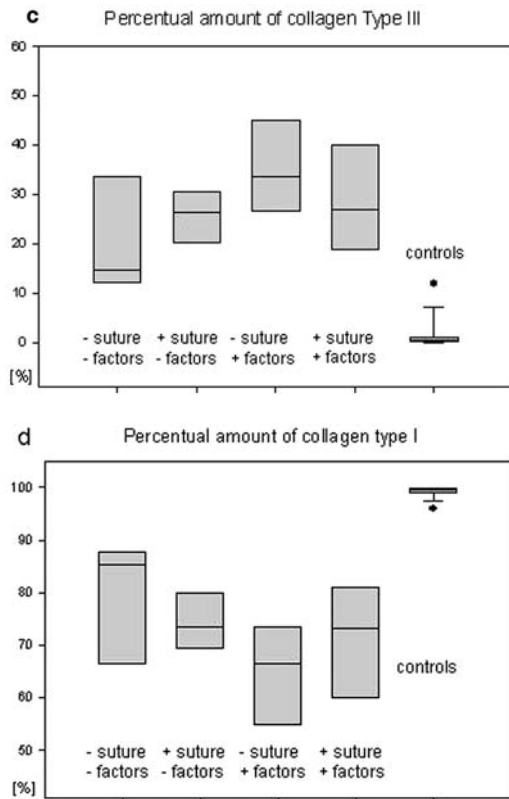




Figure 5. Picosirius-red staining of control (a) and sutured and growth factor-treated ATs (b). Note the homogeneity of the collagen fiber bundles in (a), which are mainly composed of collagen type I, which appears in polarized light in red to green. The injured ATs (b) are characterized even after 3 months by high contents of collagen type III, which appears yellow to orange. (c) and (d) show the percentual amounts of type I and type III collagen for the individual groups as determined by morphometry in the form of box plots indicating the 25th, 50th, and 75th percentiles.

Figure 6. Vessel densities in anti-CD31-stained tendon sections. (a) The right leg control section with practically no vessels present in and between collagen bundles. (b) High vessel density in AT rupture treated with suture plus growth factor application. Vessel surface areas in conservatively treated (c) and surgery animals (d), with and without factor application. Boxplots indicate the 25th, 50th, and 75th percentiles.

skin punch wound healing results with a combination of bFGF, VEGF, and PDGF than with application of individual factors. Despite this, in the present study, no significant

effects were noted. The comparatively low dosages used could be one reason for the lack of significant effects. A 3-time higher concentration of the factors, however, resulted in severe

side effects. Four animals, which overcame the side effects, were excluded from the collective and replaced. Nevertheless, they were evaluated and showed comparable results to those described in the reported collective. Thus, it seems unlikely that an insufficient dose of growth factors was responsible for the lack of significant effects.

It cannot be excluded that the combinatory growth factor approach in tendon tissues might also have adverse effects. Liu *et al* (22), for example, investigated the efficacy of combination gene therapy in an ischemic rat skin flap model. The VEGF165 plus bFGF cDNAs enhanced the viability of the flap and neovascularization most effectively, whereas addition of PDGF-B cDNA led to significant decreases in flap viability. One possible explanation may be the fact that PDGF is not only involved in the regulation of collagen synthesis but also, via stimulation of the collagenase synthesis, in collagen degradation. A temporary shift towards collagen degradation could thus explain a reduced mechanical strength (23). However, bFGF may also act on the balance of collagen synthesis and degradation through activation of collagenases (24).

Another aspect that may possibly explain the outcome of this study is that all three growth factors used are heparin binding factors that require binding to heparin sulfate proteoglycans (HSPGs) before they can bind to their respective receptors on the cell surface (25,26). Binding to HSPGs is dependent on specific modifications such as sulfation in the N-terminus. However, HSPGs present in the tissue at the time of injury are not likely to have the right motif for growth factor binding (26). Correctly modified HSPG synthesis is induced in response to injury. Knock-out studies with syndecan-1- (27) and syndecan-4-deficient mice (28) as well as with perlacan heparan sulfate-deficient mice (29) showed severe defects in tissue regeneration. From this it may be concluded that exogenous growth factor application alone may not be the correct way to stimulate tissue regeneration after injury as the process is tightly regulated, requiring also their respective receptors as well as correctly modified HSPGs.

The timing both of endogenous and exogenous growth factor release and the upregulation of the corresponding receptors is critical. In addition, early growth factor release or application within the first hours after injury into the highly protease-rich environment may result in rapid factor degradation. Therefore, the first growth factor injection immediately after surgery may have been less effective than the later applications.

Follow-up studies of this pilot study should aim to overcome the short biological half-life and early degradation of the growth factors, e.g., by embedding them in slow release fibrin and gelatin matrices (30) or microbeads (31), which are degraded later and release biologically active growth factors after the inflammatory response has ended.

In conclusion, this study demonstrated that there is a necessity for further systematic studies aimed at identifying growth factors or combinations of growth factors as well as effective release systems ensuring longer lasting activities that might lead to better functional outcomes than in our pilot combination and setting.

Furthermore, a more detailed evaluation of the optimum time points for application is warranted.

Acknowledgements

This study was made possible by a grant of the German Army (Inspection of the Sanitary Staff; M-SAB-005) to M.K. and A.W. We greatly appreciate the additional support of The Angiogenesis Foundation (Boston, MA, USA). The authors thank Dr G. Spatzkowski for surgery and animal care. We further thank our technicians Kerstin Bahr and Gisela Reifenberg for their skillful and patient assistance. This study contains parts of the doctoral thesis of F.A.

References

1. Leppilahti J, Puranen J and Orava S: Incidence of Achilles tendon rupture. *Acta Orthop Scand* 67: 277-279, 1996.
2. Khan RJK, Fick D, Keogh A, Crawford J, Brammar T and Parker M: Treatment of acute Achilles tendon ruptures. A meta-analysis of randomized, controlled trials. *J Bone Joint Surg Am* 87: 2202-2210, 2005.
3. Metz R, Verleisdonk EJ, van der Heijden GJ, Clevers GJ, Hammacher ER, Verhofstad MH and van der Werken C: Acute Achilles tendon rupture: minimally invasive surgery versus nonoperative treatment with immediate full weightbearing - a randomized controlled trial. *Am J Sports Med* 36: 1688-1694, 2008.
4. Aspenberg P: Stimulation of tendon repair: mechanical loading, GDFs and platelets. A mini-review. *Int Orthop* 31: 783-789, 2007.
5. Bolt P, Clerk AN, Luu HH, Kang Q, Kummer JL, Deng ZL, Olson K, Primus F, Montag AG, He TC, Haydon RC and Toolan BC: BMP-14 gene therapy increases tendon tensile strength in a rat model of Achilles tendon injury. *J Bone Joint Surg Am* 89: 1315-1320, 2007.
6. Forslund C and Aspenberg P: Improved healing of transected rabbit Achilles tendon after a single injection of cartilage-derived morphogenetic protein-2. *Am J Sports Med* 31: 555-559, 2003.
7. Zhang F, Liu H, Stile F, Lei MP, Pang Y, Oswald TM, Beck J, Dorsett-Martin W and Lineaweaver WC: Effect of vascular endothelial growth factor on rat Achilles tendon healing. *Plast Reconstr Surg* 112: 1613-1669, 2003.
8. Batten ML, Hansen JC and Dahners LE: Influence of dosage and timing of application of platelet-derived growth factor on early healing of the rat medial collateral ligament. *J Orthop Res* 14: 736-741, 1996.
9. Wolloscheck T, Gaumann A, Terzic A, Heintz A, Junginger T and Konerding MA: Inguinal hernia: measurement of the biomechanics of the lower abdominal wall and the inguinal canal. *Hernia* 8: 233-241, 2004.
10. Weibel ER. *Stereological Methods. I. Practical Methods for Biological Morphometry*. Academic Press, London, 1979.
11. Junqueira LCU, Bignolas G and Brentani RR: Picrosirius staining plus polarization microscopy, a specific method for collagen detection in tissue sections. *Histochem J* 11: 447-455, 1979.
12. Whittaker P, Kloner RA, Boughner DR and Pickering JG: Quantitative assessment of myocardial collagen with picrosirius red staining and circularly polarized light. *Basic Res Cardiol* 89: 397-410, 1994.
13. Lohrer H, Arentz S, Nauck T, Dorn-Lange NV and Konerding MA: The Achilles tendon insertion is crescent-shaped: an in vitro anatomic investigation. *Clin Orthop Relat Res* 466: 2230-2237, 2008.
14. Tallon C, Maffulli N and Ewen SW: Ruptured Achilles tendons are significantly more degenerated than tendinopathic tendons. *Med Sci Sports Exerc* 33: 1983-1990, 2001.
15. Schlosser MJ, Kapeghian JC and Verlangieri AJ: Selected physical and biochemical parameters in the streptozotocin treated guinea pig: insights into the diabetic guinea pig model. *Life Sci* 41: 1345-1353, 1987.
16. Ilhami K, Gokhan M, Ulukan I, Eray BM, Levent A and Cigdem T: Biomechanical and histologic comparison of Achilles tendon ruptures reinforced with intratendinous and peritendinous plantaris tendon grafts in rabbits: an experimental study. *Arch Orthop Trauma Surg* 124: 608-613, 2004.
17. Reddy GK, Stehno-Bittel L and Enwemeka CS: Matrix remodeling in healing rabbit Achilles tendon. *Wound Repair Regen* 7: 518-527, 1999.

18. Kurtz CA, Loebig TG, Anderson DD, DeMeo PJ and Campbell PG: Insulin-like growth factor I accelerates functional recovery from Achilles tendon injury in a rat model. *Am J Sports Med* 27: 363-369, 1999.
19. Hildebrand KA, Woo SL, Smith DW, Allen CR, Deie M, Taylor BJ and Schmidt CC: The effects of platelet-derived growth factor-BB on healing of the rabbit medial collateral ligament. An *in vivo* study. *Am J Sports Med* 26: 549-554, 1998.
20. Pierce GF, Mustoe TA, Senior RM, Reed J, Griffin GL, Thomason A and Deuel TA: *In vivo* incisional wound healing augmented by platelet-derived growth factor and recombinant *c-sis* gene homodimeric proteins. *J Exp Med* 167: 974-987, 1988.
21. Broughton G II, Janis JE and Attinger CE: Wound healing: an overview. *Plast Reconstr Surg* 117: 1e-S-32e-S, 2006.
22. Liu PY, Liu K, Wang XT, Badiavas E, Rieger-Christ KM, Tang JB and Summerhayes IC: Efficacy of combination gene therapy with multiple growth factor cDNAs to enhance skin flap survival in a rat model. *DNA Cell Biol* 24: 751-757, 2005.
23. Pierce GF, Berg JV, Rudolph R, Tarpley J and Mustoe TA: Platelet-derived growth factor BB and transforming growth factor beta 1 selectively modulate glycosaminoglycans, collagen, and myofibroblasts in excisional wounds. *Am J Pathol* 138: 629-646, 1991.
24. Greenhalgh DG, Sprugel KH, Murray MJ and Ross R: PDGF and FGF stimulate wound healing in the genetically diabetic mouse. *Am J Pathol* 136: 1235-1246, 1990.
25. Bishop JR, Schiksz M and Esko JD: Heparan sulphate proteoglycans fine-tune mammalian physiology. *Nature* 446: 1030-1037, 2007.
26. Lindahl U: Heparan sulfate-protein interactions - a concept for drug design? *Thromb Haemost* 98: 109-115, 2007.
27. Stepp MA, Gibson HE, Gala PH, Iglesia DD, Pajoohesh-Ganji A, Pal-Ghosh S, Brown M, Aquino C, Schwartz AM, Goldberger O, Hinkes MT and Bernfield M: Defects in keratinocyte activation during wound healing in the syndecan-1-deficient mouse. *J Cell Sci* 115: 4517-4531, 2002.
28. Cornelison DD, Wilcox-Adelman SA, Goetinck PF, Rauvala H, Rapraeger AC and Olwin BB: Essential and separable roles for Syndecan-3 and Syndecan-4 in skeletal muscle development and regeneration. *Genes Dev* 18: 2231-2236, 2004.
29. Zhou Z, Wang J, Cao R, Morita H, Soininen R, Chan KM, Liu B, Cao Y and Tryggvason K: Impaired angiogenesis, delayed wound healing and retarded tumor growth in perlecan heparan sulfate-deficient mice. *Cancer Res* 64: 4699-4702, 2004.
30. Geer DJ, Swartz DD and Andreadis ST: Biomimetic delivery of keratinocyte growth factor upon cellular demand for accelerated wound healing *in vitro* and *in vivo*. *Am J Pathol* 167: 1575-1586, 2005.
31. Zhao Y, Shimizu T, Nishihira J, Koyama Y, Kushibiki T, Honda A, Watanabe H, Abe R, Tabata Y and Shimizu H: Tissue regeneration using macrophage migration inhibitory factor-impregnated gelatin microbeads in cutaneous wounds. *Am J Pathol* 167: 1519-1529, 2005.